

FLAMINAL® IN THE MANAGEMENT OF INFECTED DRUG INJECTION SITES

Anita Kilroy-Findley. Clinical Lead Tissue Viability, Leicestershire Partnership NHS Trust. Anita.kilroy-findley@leicspart.nhs.uk

Introduction

This case study describes the management of Anna (pseudonym), a 38-year-old single parent with two young children and a 22 year history of heroin addiction who developed chronic bilateral forearm ulceration as a result of repeated subcutaneous injection (also known as “skin popping”). Whilst she does not drink, she smokes at least 40 cigarettes daily coupled with a Crack Cocaine habit and a poor diet. On admission to hospital for a 10 day detoxification programme it was noted that she had multiple infected and painful ulcers to both forearms which she had been self-managing with dry dressings.

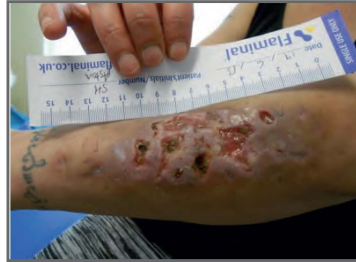

Figure 1

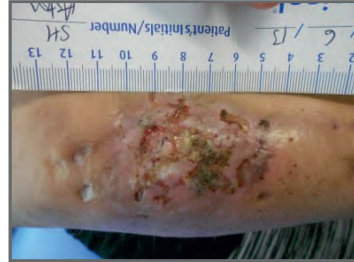

Figure 2

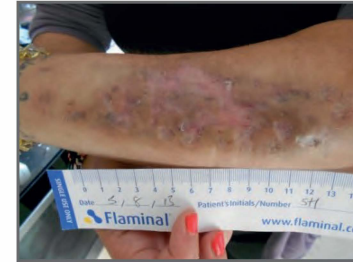

Figure 3

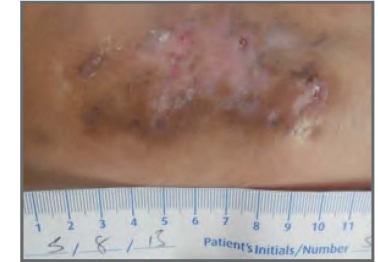


Figure 4

Method

Anna had severely indurated tissue bilaterally with multiple areas of painful exuding ulceration of which the largest area on the left arm measured 3cm x 1.3cm (fig.1) whilst the largest area on her right arm measured 3.5cm x 3cm (fig.2): both areas contained slough, some necrotic tissue and were positive for *Staphylococcus aureus*.

The aims of treatment were to autolytically debride the necrotic and sloughy tissue whilst protecting the delicate granulation tissue and peri-wound skin. It was also important to manage Anna's pain, reduce the bioburden in the wounds and control the exudate levels. Dressings were changed alternate days with Flaminal® Forte, barrier film to the peri-wound skin and a bordered silicone foam dressing applied to minimise further trauma to the already damaged surrounding skin.

Results

Anna tolerated the dressing regimen well and there was a marked improvement evident within one week with a reduction in devitalised and sloughy tissue within three weeks when Anna's left arm was almost healed, and progression to healing noted to her right forearm. Anna was able to manage the dressings herself with no pain at dressing change which reduced her anxiety levels. Both arms healed within 7 weeks meaning that she was able to contemplate plastic surgery if she remained 'clean' for a year (fig.3,4).

Discussion

There are numerous factors contributing to harm and subsequent skin problems, such as injecting technique, the injecting mixture, quantity of acid for dissolving, choice of injecting paraphernalia, selection of injecting site, longevity of injecting habits as well as underlying health and social issues.¹ Of the numerous complications linked to injection drug use, skin and soft tissue infections remain one of the most common problems with the drugs themselves causing countless adverse cutaneous and subcutaneous effects. Injecting subcutaneously increases the occurrence of infection and scarring², as does injecting with a needle that has been previously used and not properly cleaned.³

A treatment plan was devised that would treat the wounds and be acceptable to the patient as well as a regimen that Anna was able to manage easily on her discharge home. Flaminal® (Flen Health) is available in two formulations with high alginate content, which are indicated for the reduction of bacterial growth in wounds. They comprise hydrated alginate polymers in a polyethylene-glycol (PEG) matrix embedded with the enzymes glucose oxidase and lactoperoxidase to control bioburden⁴. Flaminal® has the capability to absorb excess exudate while remaining in a gelled state, promote debridement and control bioburden. Flaminal® provided antimicrobial activity to eliminate bacteria as well as autolytically debriding the wound. A heavy bacterial burden in a wound will encourage tissue degradation and slough formation especially in a patient where healing potential is further compromised by poor diet⁵ and nicotine intake.⁶

Conclusion

Debridement and reduction in the bioburden of the wound were facilitated by Flaminal® in the management of this complex patient and wounds. Dressings which reduce bacteria in a wound such as Flaminal® will help to autolytically debride slough and devitalised tissue and promote healthy granulation without causing additional pain and trauma for the patient.

References

1. Hope V, Kimber J, Vickerman P, Hickman M, Ncube F (2008) Frequency, factors and costs associated with injection site infections: findings from a national multi-site survey of injecting drug users in England BMC Infect Dis 8:1-20
2. Acquaro J (2012) Managing a chronic wound in a heroin user Wounds International 3 (4): 24-25
3. Murphy EL, DeVita D, Liu H et al (2001) Risk factors for skin and soft-tissue abscesses among injection drug users: a case-control study. Clin Infect Dis 33: 35-40
4. White R (2006) Flaminal: a novel approach to wound bioburden control. Wounds UK 2 (3): 64-9
5. Medlin S (2012) Nutrition for wound healing. BJN (Suppl) 21 (12): S11-15
6. Kean J (2010) Effects of smoking on the wound healing process. JWC 19 (1): 5-8